

Odontograms of Louis XI (1423-1483), the French king, and of Charlotte de Savoie (1441-1483), his wife

Xavier Riaud¹

Very briefly, who was Louis XI ?

Son of Charles VII, he was born on July 3, 1423. He spent his early childhood locked up in the Château de Loches, near Tours. In 1439, he was summoned by his father to restore peace in the Languedoc area which he did brilliantly but those efforts were not rewarded by the King. Louis got angry and instigated a revolution which was immediately shattered in 1440 although immediately forgiven by his father. The fightings followed one another which gave him a great reputation in the whole of Europe. A shrewd negotiator and the head of a ferocious army, he only met success. His mother died in 1445. As he did not get along with Agnès Sorel, his father's mistress, he was sent in the Dauphiné to reorganise the province. There he met Charlotte de Savoie whom he married in 1451 without his father's approval. Unhappy, the latter sent an army which failed to convince him to see reason. Then, Louis had no choice but to flee to Burgundy where he was granted refuge by Duke Philip the Good. He stayed there for five years. In 1461, Charles VII passed away. Louis became King of France. He was crowned on August 15, 1461. In 1465, he disbanded the League of the Public Weal through the trade of separate territorial concessions. The league was a coalition of feudal nobles organized in 1465 in defiance of the centralized authority. In 1467, Charles the Bold officially became Duke of Burgundy. A great rivalry started between the two men which ended with the death of the vassal in 1477 after fierce military and political battles which testified the Monarch's art of corruption to the extent of completely isolating the Duke of Burgundy until the end of his life. After numerous confrontations, weddings and subtle policies, Louis XI succeeded in rallying Picardy, Burgundy, Artois and Franche-Comté to France. On August 25, 1483, suffering from cerebral hemorrhage, the « Universal Spider » died in his château de Plessis-lès-Tours²

Louis XI, the dental art and teeth

When he was a child, Charles VII appointed Guillaume Léothier the personal doctor of the heir apparent. The doctor was in charge of the good health of the child. In 1448, as he had settled in Dauphiné of which he was the protector, the dauphin Louis hired a barber to join his personal service and lived with him in the same hotel.³

Louis XI was depicted with a « slightly prognathous face with a strong mouth and long nose.⁴ He was also described with : « ...bony cheekbones, flabby cheeks, a heavy chin, ...a disdainful mouth, ...carnivorous jaws⁵ ;... »

The operations on the teeth of Louis XI when he was an adult were carried out by Olivier le Daim, his first barber.⁶

When Louis XI allocated new statutes to barbers, doctors and surgeons in his royal ordinance of January 1465, he ordered that each of them had to have a year calendar as a codex. Therefore, before writing a prescription or carrying out an operation, they had to make sure that the location of the moon was favorable to their proceedings. Indeed, stars were said to have direct effects on the poor

¹ DDS, PhD in Epistemology, History of Sciences and Techniques, Laureate and Associate member of the National Academy of Dental Surgery.

² See Albou-Talbart Sylvie, Bernard Daniel et al., *Les rois de France [The Kings of France]*, Hachette Collections (ed.), Paris, 2006, pp. 66-69.

³ See Favier Jean, *Louis XI*, Fayard (ed.), Paris, 2001, pp. 41, 130.

⁴ See Favier Jean, *Louis XI*, op. cit., 2001, p. 45 and see Maupoint Jean, « Journal parisien de Jean Maupoint, prieur de Sainte-Catherine de la Couture (1437-1469) » [« Parisian diary of Jean Maupoint, Sainte-Catherine de la Couture's prior »], in *Mémoires de la SHPIF*, IV, 1877, pp. 1-144.

⁵ See Bordonove Georges, *Louis XI*, Pygmalion (ed.), Paris, 2008, p. 239.

⁶ See Kendall Paul Murray, *Louis XI*, Famot (ed.), Geneva, 1974, pp. 94, 207, 306, 308, 338, 354 et 359.

humanity : Saturn notably dominated the head and Mercury had effects on the mouth, the tongue and the teeth.⁷

Olivier Le Daim, his barber

Olivier Le Daim was born around 1428 and died in 1484. He was one of Louis XI's main advisers and under the former's request, he undertook a great number of diplomatic missions which were not all successful.

Originally, his real name was Olivier de Neckere, - Necker meant « water devil » - that is why he was often nicknamed « the devil ». He was the son of Jan de Neckere, a Ghent barber settled in Thielt. In 1457, as he was fleeing the kingdom of France, the dauphin Louis stayed in Thielt. There, he spent the nights in the hotel next to De Neckere's house. He became attached to the young man and made him his barber. When Louis came back to France to take over the throne, Olivier was by his side.

As a reward for his services in 1474, he was ennobled under the title Le Daim through a royal ordinance. In the same text, he was made a court nobleman and comte de Meulant despite remonstrance from the actual nobility. Nonetheless, Louis XI « devoted himself to decrease the prerogatives of his officers who only owed their statutes to the king's confidence and whom, for some of them, he no longer felt the need to have in his political entourage. As for the jurisdiction of the first barber (Olivier Le Daim) over the barbers and surgeons, it was discredited by royal bailiffs⁸. »

In 1476, Le Daim became captain of the château de Loches and governor of Saint-Quentin. As he was particularly arrogant, the new count lost no time in making enemies.

With some other specialists, Le Daim was one of the first to study prosthesis on corpses⁹. At Plessis-Tours, the château where Louis XI died in 1483, we can still find the cubbyhole where those men carried out dissections in spite of opposition from the Church. France's first operation of a man's mandible replaced with a metal one also took place in that same cubbyhole. The man who had the operation lived 29 years longer.

As for Le Daim, after the death of Louis XI, he was arrested and imprisoned by his opponents in the Conciergerie¹⁰.

He was arrested on different charges: thefts, arbitrary murders, imprisonments, etc.

Condemned to death, he was hanged at the Gallows of Montfaucon on May 21, 1484.



Olivier Le Daim and Louis XI¹¹.

⁷ See Franklin Alfred, *La vie privée d'autrefois – Les médecins* [The old private life – the doctors], Plon (ed.), Paris, 1892, pp. 76, 202-203.

⁸ See Favier Jean, *Louis XI*, op. cit., 2001, p. 364.

⁹ See Cecconi L. J., *Notes et mémoires pour servir à l'Histoire de l'Art Dentaire en France* [Notes and memoirs serving the History of Dental Art in France], L'Expansion (ed.), 1959, p. 114.

¹⁰ See Favier Jean, *Louis XI*, op. cit., 2001, p. 276.

¹¹ See Hadamard, *portrait de Louis XI et Olivier le Daim* [Portrayals of Louis XI and Olivier le Daim], (lithography). The original copy dates back to 1850.

Controversies on the discovery of the King's skull

Mystery remains as to how the skull of Louis XI was found. It was buried in Cléry¹². His remains were not sullied during the French revolution and yet, there were only five skulls in the royal grave in 1886 and only one in 1889. In the great royal sarcophagus found in the vault of the church and according to testimonies from 1792, 1818 and 1889, « the coffin contained a skull sawed in two parts. » In 1818, the previous assessment remained the same : the great sarcophagus « enclosed human bones and notably a skull sawed in two parts. » The official notice confirmed « that nothing changed... »

And yet, the confusion was due to numerous testimonies which confused extraneous remains in the royal vault.

In 1896, doctor Duchâteau did the inventory of the vault. He was the first to make the anatomical study of the bone items found in the royal coffin. He noticed five skulls in the vault among which three were in the sarcophagus. As a matter of fact, it was highly likely that the sawed skull was made up of two fragments coming from two different individuals.

In his description, Abbot Saget, the priest of Cléry, partially resumed doctor Duchâteau's observations.¹³ In his book, he quoted the following elements.

- « - The dome of the skull horizontally sawed for the embalming;
- Strong and prognathous lower jawbone;
- Upper jawbone... »

This jawbone was not mentioned in doctor Duchâteau's inventory. « Did preliminary cleaning of the great sarcophagus take place before the arrival of Abbot Saget ? Did he extract this jawbone when he left the third skull ? Did he put it back when he understood that the fragments of the sawed skull were not making a skull ? It is highly likely that this bone was there in the first place; indeed, it could be a part of the same skull but still different from that of the sawed dome of the skull ».¹⁴

As a matter of fact, during Abbot Saget's intervention in the vault, it seems that he wanted to make sure that two skulls were in the sarcophagus.¹⁵ Insofar as everybody thought that there was only one skull, he must have left behind him another skull so that the presumed skull of Louis XI would be alongside that of the presumed skull of Charlotte de Savoie.

In so doing, he dropped off the skull of a third person...

Without knowing it, he had added a third character to the couple who was already embodied by the dome of the skull and by the basis of a skull.

Therefore, beyond the act of a mere manipulation, Abbot Saget had made a mistake which he cleared in the list of his work¹⁶ published in 1913.

The computer-aided facial reconstruction

In 2001, Dr Sergueï Gorbenko, the head of the Institute of anthropological reconstruction in Lviv, Ukraine, undertook the scientific reconstitution of the monarch's face. The method, which was

¹² See Georges Patrice, « Louis XI eut-il cinq crânes ?, évolution du nombre de crânes dans le caveau royal de l'église Notre-Dame de Cléry-Saint-André (Loiret) » [« Did Louis XI have five skulls?, evolution of the number of skulls in the royal vault of the church Notre-Dame de Cléry-Saint-André (Loiret) »], in *Actes du 1^{er} colloque international de pathographie (avril 2005)* [Acts on the 1st International Conference on Pathography, April 2005], De Boccard (ed.), Paris, 2006, pp. 195-214.

¹³ See Georges Patrice, « Louis XI eut-il cinq crânes ?, évolution du nombre de crânes dans le caveau royal de l'église Notre-Dame de Cléry-Saint-André (Loiret) » [« Did Louis XI have five skulls?, evolution of the number of skulls in the royal vault of the church Notre-Dame de Cléry-Saint-André (Loiret) »], in *Actes du 1^{er} colloque international de pathographie (avril 2005)* [Acts on the 1st International Conference on Pathography, April 2005], De Boccard (ed.), Paris, 2006, pp. 195-214.

¹⁴ See Georges Patrice, « Le caveau royal de Cléry-Saint-André (Loiret) : que sont devenus les os de Louis XI? » [« The royal vault of Cléry-Saint-André (Loiret): what became of Louis XI's bones? »], in *Les dossiers d'Archéologie* [« Files on archaeology »], March 2006; 311 : 92-99.

¹⁵ See Georges P., Acquaviva C., Bruzek J. & al. « Etude du caveau royal et des sépultures de la chapelle des Dunois-Longueville de l'église Notre Dame de Cléry-Saint-André (Loiret). Approche critique des données anciennes et récentes » [« Study of the royal vault and sepulchers of the Dunois-Longueville chapel in the church Notre Dame de Cléry-Saint-André (Loiret). Critical approach to old and new data »] in *Rapport d'études et perspectives de recherches nouvelles, INRAP-SRA du Centre, Orléans, 2005*, 346 p.

¹⁶ See Saget L., *Etude sur la physionomie morale de Louis XI* [Study on Louis XI's moral physiognomy], Paris, 2nd edition, 1913.

considered, was the computer-aided craniofacial reconstruction. The face of the King of France became real following mathematical studies and the application of sculpting paste on resin casting of the skull.¹⁷

To that purpose, the researcher went to Cléry with one of his partners and all the required authorization to carry out the cast of Louis XI's skull. This mission turned out to be more perilous than he thought as the bone was incomplete and did not guarantee the certainty of a reconstruction.

Bone samples were transferred to the Molecular Genetics Laboratory of the University of Nantes.¹⁸ The DNA analyses were meant to give the missing information. Several months were required before getting the results. Indeed, there were missing bones at the intermediate and upper level of the royal skull.

Meeting with Patrice Georges of the « Institut National de Recherches Archéologiques Préventives » (the French National Institute for Preventive Archaeological Research)

M. Patrice Georges of the INRAP conducts research and studies revolving around the presumed skulls of Louis XI and Charlotte de Savoie.

While I was undertaking research on the French Kings' dental problems, I was brought to meet him. During our discussions, M. Patrice Georges disclosed the fact that the denture of the skull which was supposed to be that of Louis XI showed residual teeth. They had cavities and apical infections on them but none of these were mentioned in the expert report submitted by his team.¹⁹

The expert report released by M. Georges

On Charlotte de Savoie's mandible, we can notice lower ante-mortem tooth loss on the lower right second premolar (45) and on the first premolar of the same side which was missing before her death (44). The lower right first and second molars (46, 47) were missing. A full set of empty tooth sockets spread from the lower right canine tooth (43) to the left second premolar (35). We could also observe the ante-mortem loss of the lower left first and second molars (36,37). On a full-face photography, three tooth sockets were visible on the maxilla, those of the central left incisors (21), of the lateral left (22) and of the canine (23): all of them were empty. However, no any ante-mortem loss was noticed on the maxilla. A maxillary torus on 38 and 48 was pointed out.

As for Louis XI's skull, even though they were empty, all the tooth sockets of the right mandible were neat, except for the lower right first molar (46) which was lost before the King's death. There was another tooth. It seemed to be a lower right canine tooth (43) which showed poor occlusal wear and tear. With respect to that canine, parodontopathy was identified. We could see the tooth sockets from the lower left second premolar (35). Beyond, there was a tooth loss. The King had lost the upper left first and second molars (36, 37) before his death. As for 36, 37, 46, the healing of the alveolar bone was complete. The lower left third molar showed a radicular granuloma measuring 1,2 x 1,2 cm, its depth being unknown.²⁰

On the maxilla, two teeth remained : the canine tooth and the first right premolar (13 and 14) which showed bony lysis at the vestibular level as well as an advanced state of occlusal wear and tear. At the back, there seemed to be no teeth anymore. We could see empty tooth sockets from the upper right

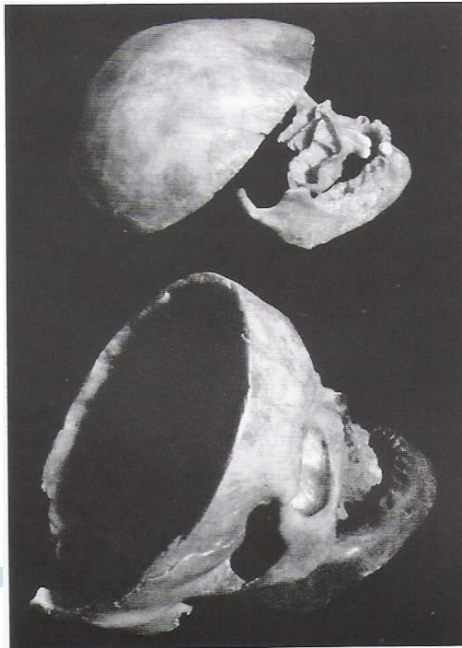¹⁷ See Lapaque Guillaume, « Louis XI révélera-t-il son visage ? » [« Will Louis XI reveal his face ? »], in *www.regioncentre.fr*, November/ December 2001, pp. 1-15.

¹⁸ See *www.Loiret.com*, « Du crâne au visage de Louis XI » [« From Louis XI's skull to face »], in *Reflets du Loiret*, 28/10/2001, n° 60, pp. 1-2.

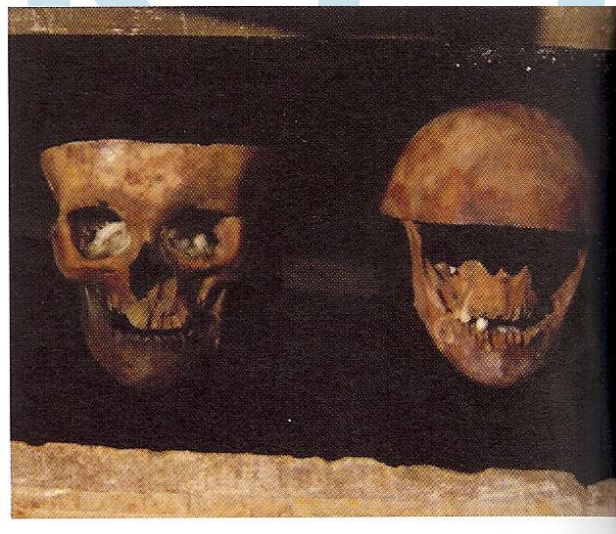¹⁹ See Georges Patrice, personal communication, Saint-Orens de Gameville, 13/02/2009 and see Charlier Ph., Georges P., Huynh-Charlier I., Carlier R. & Poupon J., « Royales dentures. Paléodontologie et pathographie » [« Royal dentures. Paleodontology and pathography »], in *Actes de la Société Française d'Histoire de l'Art Dentaire [Acts of the French Society of Dental Art History]*, Paris, 20-21/03/2009, pp. 43-46, <http://www.bium.univ-paris5.fr>

²⁰ See Georges Patrice, personal communication, Saint-Orens de Gameville, 13/02/2009 & see Charlier Ph., Georges P., Huynh-Charlier I., Carlier R. & Poupon J., « Royales dentures. Paléodontologie et pathographie » [« Royal dentures. Paleodontology and pathography »], in *Actes de la SFHAD [Acts of the French Society of Dental Art History]*, Paris, 20-21/03/2009, pp. 43-46.

first premolar (14) to the upper left canine (23).²¹ The upper right second premolar and the upper right first molar (15, 16) were missing as well as the upper left first premolar and the upper left first molar (24, 26). As for the teeth #15, 16, 24 and 26, they had been missing before the King's death and the alveolar bone was completely healed.²²



Skulls attributed to Louis XI at the top and to Charlotte de Savoie at the bottom²³.



Skulls attributed to Louis XI on the right and to Charlotte de Savoie on the left²⁴.

Results

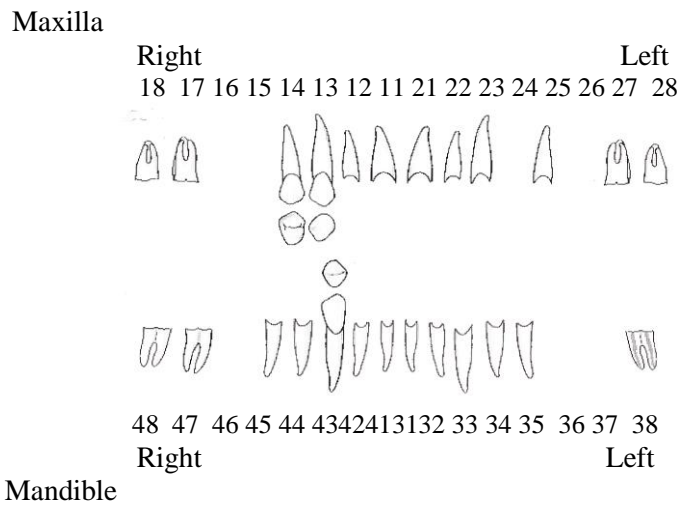
²¹ See Georges Patrice, « Le caveau royal de Cléry-Saint-André (Loiret) : que sont devenus les os de Louis XI ? » [«The royal vault of Cléry-Saint-André (Loiret): what became of Louis XI's bones»], in *Les dossiers d'Archéologie* [«Files on archaeology»], March 2006; 311 : 92-99.

²² See Georges Patrice, personal communication, Saint-Orens de Gameville, 13/02/2009 & see Charlier Ph., Georges P., Huynh-Charlier I., Carlier R. & Poupon J., « Royales dentures. Paléodontologie et pathographie » [«Royal dentures. Paleodontology and pathography»], in *Actes de la SFHAD* [Acts of the French Society of Dental Art History], Paris, 20-21/03/2009, pp. 43-46.




²³ See Georges Patrice, INRAP, Saint-Orens de Gameville, 2007, © PG.

²⁴ See Georges Patrice, INRAP, Saint-Orens de Gameville, 2007, © PG.

Post-mortem dental schema of Louis XI's presumed skull (1423-1483)²⁵:



Legend:

-  : Empty tooth socket (post-mortem lost tooth).
-  : Empty tooth socket (post-mortem lost tooth) showing a radicular cyst.
-  : Tooth in its original tooth socket.

Reminder:

- Ancient ante-mortem dental loss of teeth #36, 37 and 46 on the mandible with complete healing of the alveolar bone.
- Ancient ante-mortem dental loss of teeth #15, 16, 24 and 26 on the mandible with complete healing of the alveolar bone.
- Radicular cyst on tooth #38 measuring 1,2 x 1,2 cm (unknown depth).
- Tooth #43 with poor occlusal wear and tear.
- Teeth #13 and 14 with a more obvious occlusal wear and tear.

Remark:

« By far, tooth #43 looked like a bicuspid tooth close to a lower premolar. There was an advanced bone loss with respect to teeth #15 and 16, and the little abrasion of the residual teeth was highly surprising for a 60-year-old man considering the very abrasive diet of the time. Is it likely to give these remains an approximate age and to confirm their identity? The issue is still raised.²⁶ »

The ante-mortem missing teeth with complete bone healing suggest that Olivier Le Daim, Louis XI's personal barber and presumed dentist of the time, might have extracted them.

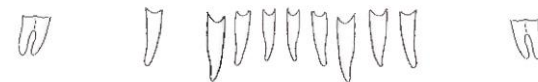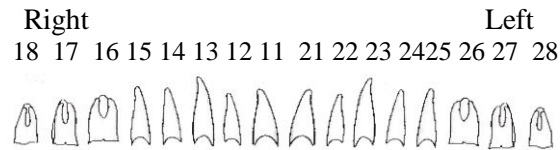
²⁵ See Riaud Xavier, Saint Herblain, 2009, © Riaud Xavier.

The above and following dental schemas were made thanks to photographs of Louis XI's and Charlotte de Savoie's presumed skulls that Patrice Georges kindly lent me. They were examined and confirmed by doctor Franck Domart, dental surgeon, which carried out the dental proficiency examination (1995; report published in 2006 by Editions de Boccard) of Saint Roseline's remains (v. 1270-1329).

²⁶ See Georges Patrice, personal communication, Saint-Orens de Gameville, 13/02/2009 & see Charlier Ph., Georges P., Huynh-Charlier I., Carlier R. & Poupon J., « Royales dentures. Paléodontologie et pathographie » [«Royal dentures. Paleodontology and pathography»], in *Actes de la SFHAD [Acts of the French Society of Dental Art History]*, Paris, 20-21/03/2009, pp. 43-46.

Post-mortem dental schema of Charlotte de Savoie 's presumed skull (1441-1483)²⁷

Maxilla



48 47 46 45 44 43 42 41 31 32 33 34 35 36 37 38
Right Left

Mandible

Legend:

: Empty tooth socket (post-mortem lost tooth).

Reminder:

- Ancient ante-mortem dental loss of teeth # 44, 46, 47, 36 and 37 on the mandible.²⁸
- Mandibular torus regarding teeth #38.
- Mandibular torus regarding teeth #48.

Remark:

Even though there was no mirroring ante-mortem loss, given the fact that there was complete antagonistic bone healing, teeth #16 and 17 should have extruded and left shorter tooth sockets. It was the same thing for teeth #26 and 27.

Bibliography:

- Albou-Talbart Sylvie, Bernard Daniel et al. *Les rois de France [The Kings of France]*, Hachette Collections (ed.), Paris, 2006.
- Bordonove Georges, *Louis XI*, Pygmalion (ed.), Paris, 2008.
- Cecconi L. J., *Notes et mémoires pour servir à l'Histoire de l'Art Dentaire en France [Notes and memoirs serving the History of Dental Art in France]*, L'Expansion (ed.), 1959.
- Charlier Ph., Georges P., Huynh-Charlier I., Carlier R. & Poupon J., « Royales dentures. Paléodontologie et pathographie » [«Royal dentures. Paleodontology and pathography»], in *Actes de la Société Française d'Histoire de l'Art Dentaire [Acts of the French Society of Dental Art History]*, Paris, 20-21/03/2009, pp. 43-46, <http://www.bium.univ-paris5.fr>.
- Favier Jean, *Louis XI*, Fayard (ed.), Paris, 2001.
- Franklin Alfred, *La vie privée d'autrefois – Les médecins [The old private life – the doctors]*, Plon (ed.), Paris, 1892.
- Georges P., Acquaviva C., Bruzek J. & al., « Etude du caveau royal et des sépultures de la chapelle des Dunois-Longueville de l'église Notre Dame de Cléry-Saint-André (Loiret). Approche critique des données anciennes et récentes » » [«Study of the royal vault and sepulchers of the Dunois-Longueville chapel in the church Notre Dame de Cléry-Saint-André (Loiret). Critical approach to old

²⁷ See Riaud Xavier, Saint Herblain, 2009, © Riaud Xavier.

²⁸ See Georges Patrice, personal communication, Saint-Orens de Gameville, 13/02/2009 & see Charlier Ph., Georges P., Huynh-Charlier I., Carlier R. & Poupon J., « Royales dentures. Paléodontologie et pathographie » [«Royal dentures. Paleodontology and pathography»], in *Actes de la SFHAD [Acts of the French Society of Dental Art History]*, Paris, 20-21/03/2009, pp. 43-46.

and new data], in *Rapport d'études et perspectives de recherches nouvelles*, INRAP-SRA du Centre, Orléans, 2005, 346 p.

Georges Patrice, « Louis XI eut-il cinq crânes ?, évolution du nombre de crânes dans le caveau royal de l'église Notre-Dame de Cléry-Saint-André (Loiret) » [« Did Louis XI have five skulls?, evolution of the number of skulls in the royal vault of the church Notre-Dame de Cléry-Saint-André (Loiret) »], in *Actes du 1^{er} colloque international de pathographie (avril 2005)* [Acts on the 1st International Conference on Pathography, April 2005], De Boccard (ed.), Paris, 2006, pp. 195-214.

Georges Patrice, « Le caveau royal de Cléry-Saint-André (Loiret) : que sont devenus les os de Louis XI ? » [«The royal vault of Cléry-Saint-André (Loiret): what became of Louis XI's bones»], in *Les dossiers d'Archéologie* [Files on archaeology], March 2006; 311 : 92-99.

Georges Patrice, personal communication, Saint-Orens de Gameville, 2007 and 13/02/2009.

Hadamard, *portrait de Louis XI et Olivier le Daim* (lithographie) [Portrayals of Louis XI and Olivier le Daim (lithography)], 1850.

Kendall Paul Murray, *Louis XI*, Famot (ed.), Geneva, 1974.

Lapaque Guillaume, « Louis XI révélera-t-il son visage ? » [«Will Louis XI reveal his face?»], in *www.regioncentre.fr*, November/ December 2001, pp. 1-15.

Maupoint Jean, « Journal parisien de Jean Maupoint, prieur de Sainte-Catherine de la Couture (1437-1469) » [« Parisian diary of Jean Maupoint, Sainte-Catherine de la Couture's prior »], in *Mémoires de la SHPIF*, IV, 1877.

Riaud Xavier, private collection, Saint Herblain, 2009.

Saget L., *Etude sur la physionomie morale de Louis XI* [Study on Louis XI's moral physiognomy], Paris, 2nd edition, 1913.

www.Loiret.com, « Du crâne au visage de Louis XI » [« From Louis XI's skull to face »], in *Reflets du Loiret*, 28/10/2001, n° 60, pp. 1-2.

